Letter to the Editor
Diagnostic Hematology

Ann Lab Med 2023;43:100-103
https://doi.org/10.3343/alm.2023.43.1.100
ISSN 2234-3806 eISSN 2234-3814

ANNALS OF LABORATORY MEDICINE

A Case of *STIL-TAL1*-positive T-lymphoblastic Leukemia With a Minor Philadelphia-positive Clone

Yu-Kyung Koo, M.D., Hongkyung Kim, M.D., and Saeam Shin, M.D.
Department of Laboratory Medicine, Yonsei University College of Medicine, Severance Hospital, Seoul, Korea

Dear Editor,

The Philadelphia chromosome (Ph) results from the reciprocal translocation t(9;22)(q34.1;q11.2) and comprises the *BCR-ABL1* fusion [1,2]. In B lymphoblastic (B)-ALL/lymphoblastic lymphoma (LBL), Ph+ cases account for ~25% of adult cases and 2%–4% of pediatric cases. It is associated with poor prognosis and requires therapy with tyrosine kinase inhibitors (TKIs) [3]. In contrast, Ph+ T-ALL/LBL is so rare that the clinical relevance, prognostic significance, and treatment approaches are not clearly defined for these patients [1, 4, 5].

STIL-TAL1 fusion is identified in 9%–26% of T-ALL cases and results from interstitial deletion between the 5′ untranslated region of *TAL1* and *STIL*, located on chromosome 1p33. This condition can promote T-cell leukemogenesis due to *TAL1* overexpression; however, its clinical significance is controversial [6].

We report a rare case of a *STIL-TAL1*-positive T-ALL patient who also carried a minor Ph+ clone. The Institutional Review Board of Severance Hospital, Seoul, Korea, approved this study (4-2022-0305) and waived the need for informed consent.

An 11-year-old boy with no significant medical history presented with a cervical mass. He underwent cervical lymph node biopsy at a tertiary hospital in February 2022; the pathologic diagnosis was suggestive of precursor T-cell lymphoid neoplasm. The patient was referred to our hospital for further evaluation and was admitted to the isolation ward after testing positive for coronavirus disease (COVID-19).

Complete blood count was white blood cell (WBC) count, 252.55×10^9/L; hemoglobin, 10.3 g/dL; platelet count, 47×10^9/L. Peripheral blood smear showed 89% blasts (Fig. 1A). Because of COVID-19, initial bone marrow examination was not performed; the entire diagnostic work-up was conducted using peripheral blood samples. Chromosome analysis results were not interpretable because of a lack of metaphase cells. Flow cytometry showed an abnormal leukemic population, consistent with T-ALL/LBL (Fig. 2). Reverse transcription (RT)-PCR using total RNA isolated from WBCs (HemaVision kit; DNA-Diagnostic, Risskov, Denmark) revealed an e1a2 rearrangement (Fig. 1B). Quantitative RT-PCR (Ipsogen BCR-ABL1 mbcr kit; Qiagen, Hilden, Germany) revealed a *BCR-ABL1*-to-*ABL1* transcript ratio of 6.11×10^{-4}. RNA fusion panel (FusionPlex Pan-Heme Panel, ArcherDX, CO, USA) detected a *STIL-TAL1* rearrangement (Fig. 1C).

To confirm the *STIL-TAL1* transcript, RT-PCR and direct sequencing were performed (Fig. 1D, E). Next-generation sequencing revealed a copy number loss of *CDKN2A/B* and two frameshift mutations of *PTEN* exon 7 in trans (p.Leu247LysfsTer11, 11.3% variant allele frequency [VAF] and p.Leu247HisfsTer14, 43.7% VAF), which are frequently associated with T-ALL [7]. A *TCR* gene clonality assay (LymphoTrack; Invivoscribe Technologies, San Diego, CA, USA) showed clonal rear-

Received: May 6, 2022
Revision received: June 17, 2022
Accepted: August 12, 2022

Corresponding author: Saeam Shin, M.D.
Department of Laboratory Medicine, Yonsei University College of Medicine, Severance Hospital, 50-1 Yonsei-ro, Seodaemun-gu, Seoul 03722, Korea
Tel: +82-2-2228-2453, Fax: +82-2-364-1583, E-mail: saeam0304@yuhs.ac

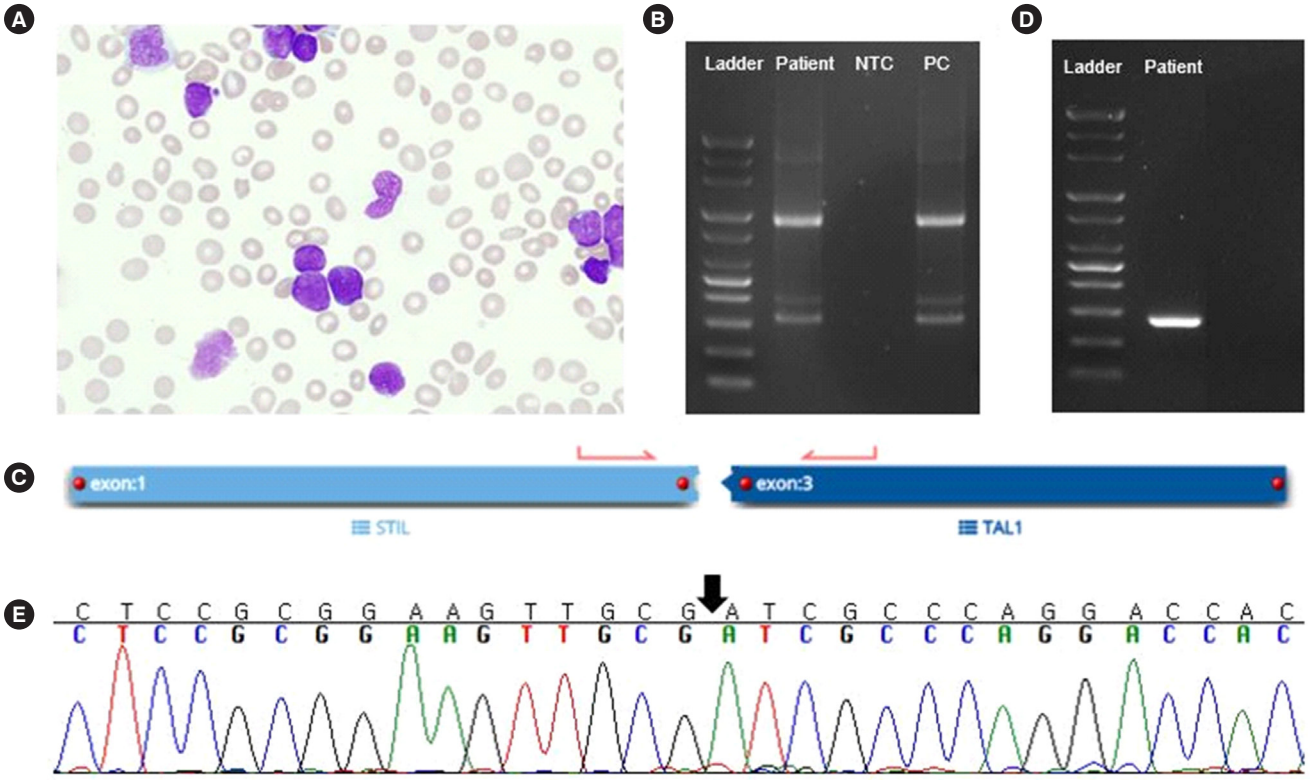

Fig. 1. Morphological and genetic analysis. (A) Blasts on a peripheral blood smear (Wright–Giemsa stain, 1,000×). (B) Agarose gel electrophoresis of the reverse transcription (RT)-PCR product showing the e1a2 (p190) *BCR-ABL1* transcript (HemaVision kit; DNA-Diagnostic, Risskov, Denmark). (C) *STIL-TAL1* fusion detected using an RNA fusion panel (FusionPlex Pan-Heme Panel; ArcherDX, Boulder, CO, USA). (D) RT-PCR using cDNA and subsequent (E) Sanger sequencing confirmed breakpoints in exons 1 and 3 of *STIL* and *TAL1*, respectively.
Abbreviations: NTC, non-template control; PC, positive control.

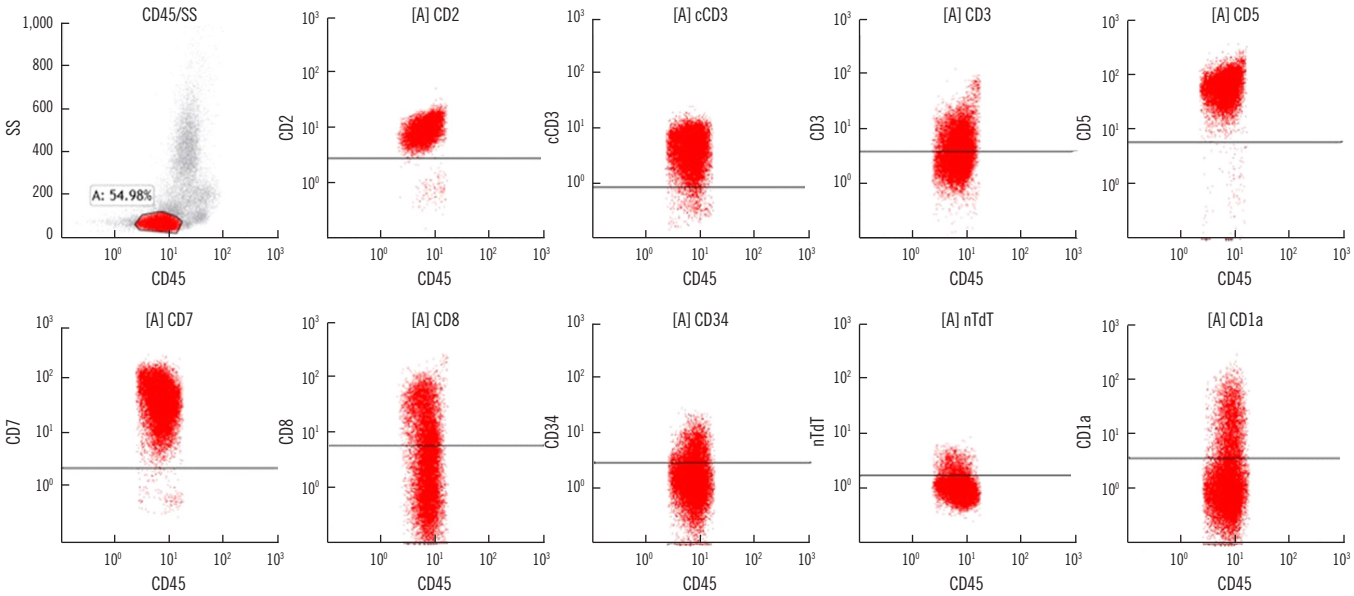

Fig. 2. Flow cytometry findings of the patient. Abnormal leukemic cells highlighted in red (55.0% of total cells) exhibited a $CD2^{+}$, $cCD3^{+}$, $CD3^{+,dim}$, $CD5^{+}$, $CD7^{+}$, $CD8^{+,dim}$, $CD34^{-}$, $nTdT^{-}$, and $CD1a^{-}$ phenotype at diagnosis.
Abbreviations: cCD3, cytoplasmic CD3; SS, side scatter.

rangement in *TCRB* (Db1/Jb1-2; 40.1% of total reads) and *TCRG* (Vg3/none; 40.8% of total reads).

In our case, *BCR-ABL1* fusion was detected only by RT-PCR, not by RNA fusion panel analysis. The reason for this discrepancy maybe the different levels of sensitivity of the two tests [8]. Based on a previous report describing cases of T-ALL with a minor Ph+ clone [9], our case can be considered *STIL-TAL1*-positive T-ALL with a minor Ph+ clone. The patient received induction therapy and achieved complete remission with incomplete hematologic recovery. He continued treatment with nelarabine, and hematopoietic stem cell transplantation is planned after consolidation therapy with the addition of imatinib.

Ph+ T-ALL/LBL is extremely rare, and only a few cases have been reported [1, 4, 5]. Furthermore, Ph+ T-ALL with *STIL-TAL1* fusion has been reported only once [10]. To our knowledge, this is the first case of Ph+ T-ALL as well as of Ph+ T-ALL with *STIL-TAL1* fusion reported in Korea.

Because of its rarity, the clinical significance of Ph+ clones in Ph+ T-ALL is not clearly defined. However, as expression of the *BCR-ABL1* oncogene provides proliferative and survival advantages, there may be risk of clonal selection of Ph+ clones, possibly contributing to the worsening of the prognosis. This can be implied from a Ph+ T-ALL case in which disease progression was associated with a higher *BCR-ABL1* transcript level and an increase in proportion of *BCR-ABL1*-positive cells, indicating the contribution of Ph+ clones in disease progression, leading to a poor outcome [1, 11]. As for the treatment approach of Ph+ T-ALL, the addition of TKIs to chemotherapy should be considered as cases in which patients showed good responses to TKIs have been reported [9].

We report a rare case of *STIL-TAL1*-positive T-ALL with a minor Ph+ clone. More extensive studies are needed to assess the true incidence of T-ALL with a minor Ph+ clone and its clinical significance. Moreover, research on the role of these coexisting rearrangements in leukemogenesis is warranted. Clinical laboratories should be aware of this rare phenomenon and use caution when reporting patients' test results.

ACKNOWLEDGMENTS

We thank the patient involved in this study and his parents.

AUTHOR CONTRIBUTIONS

Koo YK collected patient data and wrote the manuscript. Kim H performed the genetic and flow cytometric analyses. Shin S supervised the research and reviewed and edited the manuscript. All authors reviewed and approved the final version of the manuscript.

CONFLICTS OF INTEREST

There are no potential conflicts of interest relevant to this article to report.

RESEARCH FUNDING

This work was supported by the National Research Foundation of Korea (NRF-2021R1I1A1A01045980).

ORCID

Yu-Kyung Koo https://orcid.org/0000-0002-4390-7679
Hongkyung Kim https://orcid.org/0000-0003-4185-1672
Saeam Shin https://orcid.org/0000-0003-1501-3923

REFERENCES

1. Li X, Ping N, Wang Y, Xu X, Gao L, Zeng Z, et al. Case report: a case with Philadelphia chromosome positive T-cell lymphoblastic lymphoma and a review of literature. Front Oncol 2020;10:584149.
2. Choi H, Cho SR, Yang D, Lee W, Hwang H, Lee HS, et al. A Case of Preleukemic Chronic Myeloid Leukemia Following Chemotherapy and Autologous Transplantation for T-lymphoblastic Lymphoma. Ann Lab Med 2020;40:417-20.
3. Swerdlow SH, Campo E, et al. eds. WHO Classification of tumours of haematopoietic and lymphoid tissues. 4th ed. WHO classification of tumours, 2017; volume 2.
4. Raanani P, Trakhtenbrot L, Rechavi G, Rosenthal E, Avigdor A, Brok-Simoni F, et al. Philadelphia-chromosome-positive T-lymphoblastic leukemia: acute leukemia or chronic myelogenous leukemia blastic crisis. Acta Haematol 2005;113:181-9.
5. Jain P, Kantarjian H, Jabbour E, Kanagal-Shamanna R, Patel K, Pierce S, et al. Clinical characteristics of Philadelphia positive T-cell lymphoid leukemias-(De novo and blast phase CML). Am J Hematol 2017;92:E3-4.
6. D'Angiò M, Valsecchi MG, Testi AM, Conter V, Nunes V, Parasole R, et al. Clinical features and outcome of SIL/TAL1-positive T-cell acute lymphoblastic leukemia in children and adolescents: a 10-year experience of the AIEOP group. Haematologica 2015;100:e10-3.
7. Furness CL, Mansur MB, Weston VJ, Ermini L, van Delft FW, Jenkinson S, et al. The subclonal complexity of STIL-TAL1+ T-cell acute lymphoblastic leukaemia. Leukemia 2018;32:1984-93.
8. Kim B, Lee H, Shin S, Lee ST, Choi JR. Clinical evaluation of massively parallel RNA sequencing for detecting recurrent gene fusions in hematologic malignancies. J Mol Diagn 2019;21:163-70.
9. Prebet T, Mozziconacci MJ, Sainty D, Arnoulet C, Lafage M, Dastugue N, et al. Presence of a minor Philadelphia-positive clone in young adults with *de novo* T-cell ALL. Leuk Lymphoma 2009;50:485-7.
10. Chen X, Wang F, Zhang Y, Wang M, Tian W, Teng W, et al. Retrospective

analysis of 36 fusion genes in 2479 Chinese patients of *de novo* acute lymphoblastic leukemia. Leuk Res 2018;72:99-104.
11. Tchirkov A, Bons JM, Chassagne J, Schoepfer C, Kanold J, Briançon G, et al. Molecular detection of a late-appearing BCR-ABL gene in a child with T-cell acute lymphoblastic leukemia. Ann Hematol 1998;77:55-9.